

Case Series

Optimizing the Esthetic Potential of Implant Restorations Through the Use of Immediate Implants With Immediate Provisionals

Brien V. Harvey*

Background: Few things in clinical periodontics are more challenging or potentially more rewarding than gaining an ideal result with implant-supported crowns in the esthetic zone.

Methods: This article describes a novel approach to maintaining soft tissue health and support following immediate implant placement and immediate insertion of minimally functional single-unit screw-retained fixed provisionals.

Results: Excellent tissue health, soft tissue profiles, and maintenance of septal bone height are documented with clinical photographs and 1-year follow-up radiographs.

Conclusion: In addition to maximizing the chances for an optimal esthetic result, this technique also allows precise adjustment and stability of occlusal relationships for provisionals in the perioperative period. *J Periodontol* 2007;78:770-776.

KEY WORDS

Dental esthetics; dental implants.

Providing patients with optimal esthetics remains challenging when teeth require replacement with implant-supported crowns. However, it can be a source of great satisfaction for the patient and the practitioner when the outcome is excellent. Maintenance of soft tissue contours is requisite in gaining ideal esthetic outcomes in cases where the gingival margin is displayed when the patient speaks or smiles. In turn, maintenance of soft tissue contours is dependent on atraumatic extraction techniques followed by providing support for the overlying soft tissues during the postextraction healing period. Optimal support of the soft tissues during healing following loss of a tooth in the esthetic zone might best be provided through immediate implant placement and insertion of an immediate, minimally functional fixed provisional. This article describes a novel approach to immediate provisionalization in the esthetic zone.

The techniques illustrated in this case report were undertaken on patients treated by the author in a solo periodontal practice in Tucson, Arizona. This practice (and practitioner) had participated in an observational investigation in 2004 that included >500 patients treated in >150 practices.^{1,2} The protocol of this study included multiple implants in partially edentulous patients, with a single-stage surgical approach, either to include use of healing cuffs or immediate fixed provisionals. Based on the author's favorable experiences in this study, including excellent healing for all seven study patients treated by him, the decision was made in late 2004 to begin offering immediate fixed provisionals for patients receiving implants, in most cases immediate implants, in the esthetic zone. It is the author's clinical opinion that a well-designed provisional allows esthetic temporary replacement of an anterior tooth or teeth while posing minimal risk of adversely affecting the initial stages of integration. In some respects, an esthetic fixed provisional that is adjusted to avoid occlusal contacts in centric occlusion and in excursive movements seems analogous

* Private practice, Tucson, AZ.

to a tall thin healing cuff or abutment, and single-stage implant surgeries have an excellent track record of safety and efficacy. During an 18-month period (November 2004 to May 2006), 36 maxillary anterior teeth were treated in the fashion described in this article.

MATERIALS AND METHODS

Each patient was diagnosed with a hopeless maxillary anterior tooth (or teeth), and an agreement was reached that replacing the tooth with an implant-supported crown was the treatment of choice. Informed consent was obtained for intravenous sedation, tooth removal, implant placement, and insertion of an immediate fixed provisional. The two patients profiled in the present report provided signed, informed consent for inclusion in this publication. All 36 patients treated in the manner described in this report were managed in a fashion consistent with the Helsinki Declaration, as revised in 2000.

All patients were given prescriptions for systemic antibiotics, with the first dose taken 1 hour before surgery. Antibiotic coverage was continued for the first postoperative week. Intravenous access was gained using a 19-gauge butterfly, 20 ml whole blood was drawn, and the blood was centrifuged and managed in a fashion as recommended by the manufacturer[†] to obtain ~2 ml of platelet-rich plasma (PRP). Titration of intravenous conscious sedation was then undertaken, almost exclusively with midazolam as a single-agent sedative. After the patient was sedated the surgical site was anesthetized, most commonly using 0.5% bupivacaine.

Following anesthesia, the tooth was removed using periostomes, allowing removal of the root without elevation of a flap. The extraction site was debrided, as needed, and the implant osteotomy was then prepared with harvesting of the autogenous bone through use of a disposable bone trap.[‡] On completion of the osteotomy, an endosseous implant was placed with the fixture platform positioned at or just apical to the osseous crest on the mid-labial aspect of the socket. Insertion of the implant was completed using a manual torque wrench set to 25 Ncm. The implants used for the cases described in this article include a textured, fluoride-treated surface with microthreads extending to the bevel that defines the platform.[§] Additionally, the design of these implants includes a double hex-indexed internal machined conical abutment-implant interface. The socket was filled with PRP immediately before implant placement, and any gaps wider than 1 mm between the socket and the implant were grafted using a combination of autogenous bone particles with PRP. Perforations of the buccal cortical plate, such as are frequently encountered with teeth having histories of prior apical surgery (e.g.,

case 1 in this report), were grafted through the socket, also with autogenous bone and without elevation of a flap. On rare occasions, the autogenous bone was supplemented with freeze-dried allogenic bone.^{||} Neither of the cases presented in this report required supplemental bone.

The existing clinical crown, whether a porcelain fused to metal (PFM) crown (case 1) or a tooth-with-veneer (case 2), or a natural tooth with or without intracoronal restorations (not illustrated) was then relieved to fit over and around a screw-retained temporary abutment inserted into the implant, and the crown was luted to the abutment intraorally using flowable light-cured composite. The crown and abutment were then removed as a single piece so that the provisional could be finished extraorally. When completed, the provisional was inserted back into the implant to allow careful adjusting of the occlusion, avoiding contact between the provisional and the opposing tooth or teeth in centric occlusion and in protrusive and lateral movements.

When all adjustments were complete, the provisional was tightened using firm finger pressure with a manual hex drive, and the screw access opening was closed using cotton and a plaster-based filling material. Postoperative instructions included cautioning the patient to avoid functioning (chewing food or other objects) against the provisional. The patient was then seen for postoperative visits as needed, including at least one early (7 to 10 days) postoperative visit, with a follow-up radiograph at ~3 months.

All cases healed with favorable labial gingival contours and apparently favorable crestal bone height (no posthealing bone sounding or exploratory flaps were undertaken). Two patients, including case 1 illustrated in this article, had their antibiotic coverage extended for a second week because of pronounced tenderness over the apical aspect of the implant site. Of the 36 immediate implants, immediate provisional cases replacing maxillary anterior teeth during this 18-month period, 35 were completed with no flap and no sutures, whereas just one (a trauma case that included loss of most of the labial cortical plate) necessitated elevation of a flap.

CASE 1

The patient, a 62-year-old woman, suffered non-restorable structural failure of the maxillary left lateral incisor (tooth #10; vertical root fracture [Fig. 1A]). The preoperative radiograph, taken before the crown and post had come out (Fig. 1B), documents favorable alveolar ridge height. Following removal of the tooth,

[†] Harvest Technologies, Plymouth, MA.

[‡] BoneTrap, Astra Tech USA, Waltham, MA.

[§] Osseospeed, Astra Tech USA.

^{||} Puros, Zimmer Dental, Carlsbad, CA.

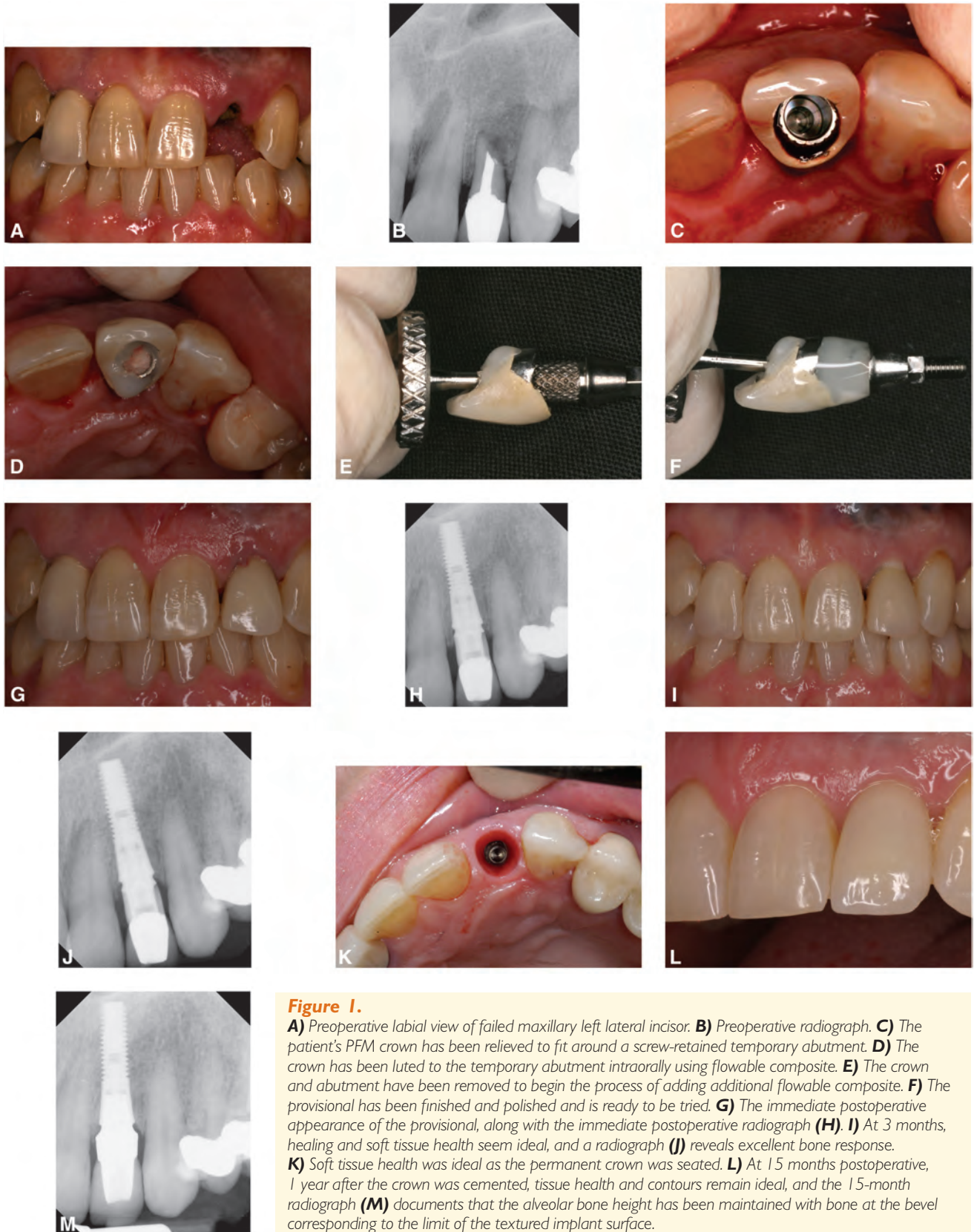


Figure 1.

A) Preoperative labial view of failed maxillary left lateral incisor. **B)** Preoperative radiograph. **C)** The patient's PFM crown has been relieved to fit around a screw-retained temporary abutment. **D)** The crown has been luted to the temporary abutment intraorally using flowable composite. **E)** The crown and abutment have been removed to begin the process of adding additional flowable composite. **F)** The provisional has been finished and polished and is ready to be tried. **G)** The immediate postoperative appearance of the provisional, along with the immediate postoperative radiograph (**H**). **I)** At 3 months, healing and soft tissue health seem ideal, and a radiograph (**J**) reveals excellent bone response. **K)** Soft tissue health was ideal as the permanent crown was seated. **L)** At 15 months postoperative, 1 year after the crown was cemented, tissue health and contours remain ideal, and the 15-month radiograph (**M**) documents that the alveolar bone height has been maintained with bone at the bevel corresponding to the limit of the textured implant surface.

the implant osteotomy was prepared, the implant was inserted, a temporary abutment was screwed into place, and the patient's porcelain-fused-to-metal crown was relieved to fit around the temporary abutment (Fig. 1C). The crown was then luted in place using flowable light-cured composite (Fig. 1D), and was unscrewed from the implant and removed from the mouth (Fig. 1E). Additional flowable composite was added and cured extraorally, and the provisional was then finished and polished (Fig. 1F).

Once finished and polished, the provisional crown was screwed into the implant, and the occlusion was checked and adjusted to eliminate centric and lateral-protrusive contacts. The immediate postoperative photograph (Fig. 1G) and radiograph (Fig. 1H) reveal favorable implant placement and appropriate contours of the provisional restoration.

Three months following implant and provisional placement, a clinical assessment and photograph (Fig. 1I) revealed excellent tissue health, and a radiograph (Fig. 1J) revealed maintenance of interproximal crestal bone height. The patient was then referred back to her restorative dentist for fabrication of the zirconium abutment and crown. Soft tissue health and contours were noted to be ideal (Fig. 1K) on the day that the crown was cemented. The patient was seen 15 months postoperative for a follow-up photograph (Fig. 1L) and a radiograph (Fig. 1M), documenting excellent maintenance of tissue health, bone height, and esthetic outcome.

CASE 2

The patient, a 52-year-old woman, suffered non-restorable structural failure of tooth #8, in this case a complete mesial-distal chisel fracture extending into (and being held in place at the moment of fracture by only) the labial attachment (Fig. 2A). A radiograph (Fig. 2B) documented favorable alveolar bone height. This tooth had a history of trauma nearly 30 years before the recent fracture, followed by discoloration of the tooth over a period of years. Because the tooth reportedly remained vital (responsive) at the time of discoloration, and because external bleaching was ineffective, the patient elected to have a veneer. Subsequently, the tooth did become non-vital and abscessed, necessitating endodontic therapy ~15 years before its fracture. The original veneer remained in place.

Following removal of the extracoronary splint, the tooth was removed in two pieces (Fig. 2C). With careful, judicious use of periostomes, the author managed to remove the root without elevation of a flap. In a manner essentially identical to the treatment sequence described in case 1, the tooth and its veneer were attached to a temporary abutment, with subsequent

finishing as a screw-retained provisional (Figs. 2D through 2G). As with case 1, the immediate postoperative radiograph (Fig. 2H) reveals favorable implant placement and provisional contours.

In case 2, the patient elected to have the implant crown fabricated and placed while she was away from Tucson for the summer. The permanent restoration is shown (Figs. 2I and 2J) 12 months following implant placement. The 12-month radiograph (Fig. 2K) reveals maintenance of crestal bone height on the proximals of the adjacent teeth and bone contact with the implant very near the bevel corresponding to the junction between the textured surface and the machined titanium.

DISCUSSION

The two cases presented here are representative of the outcomes obtained by the author in managing 36 immediate implant, immediate provisional cases over an 18-month period. The provisionalization stage of the surgical appointment has been time consuming, averaging 30 to 40 minutes of chair time following placement of each implant. Given the fact that patients leave with "their own" tooth in place, feedback following these procedures has been extremely favorable. Whether because of the use of PRP, the lack of elevation of a flap, or atraumatic extractions through use of periostomes, reports from the patients concerning their postoperative comfort also have been positive. Although not quantified on a visual pain scale, anecdotally the pain levels have tended to range from "none" to "very little." It has been the exception when patients return for their postoperative visits and report that they needed any opiate analgesics.

Relieving existing porcelain and porcelain-fused-to-metal crowns for use as provisional crowns, as described and shown in this article, can be challenging. A diamond burr in a high-speed handpiece is effective for removal and recontouring of the porcelain, whereas a carbide burr designed for cutting through metal can be used to penetrate the metal coping. On occasion, the porcelain has fractured in the process of fabricating the provisional, and the author always requests a back-up composite crown or denture tooth from the restorative dentist for cases involving preexisting porcelain or porcelain-fused-to-metal crowns.

Natural teeth or teeth with veneers, as shown in case 2, have posed no problems with fracture for the author. Additionally, as shown in Figure 2D, the ability to bond to the dentin and enamel of the internally relieved tooth, rather than carefully hollowing out the crown to fit around the abutment (as in Fig. 1C), facilitates the process of fabricating the provisional. Once fabricated and inserted, the provisionals have generally proved to require little in the way of professional intervention during the period between

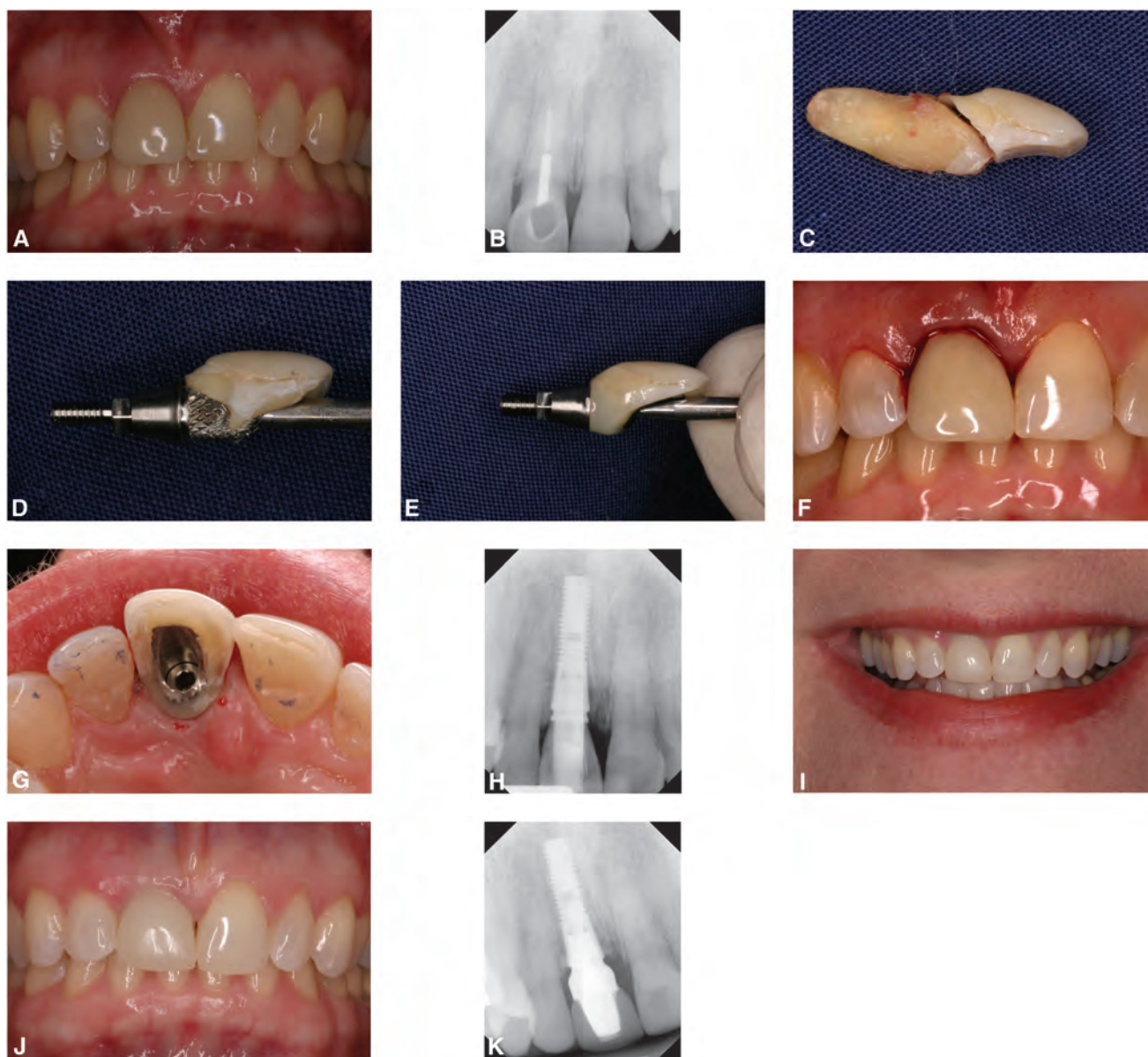


Figure 2.

A) Preoperative labial and radiographic views (**B**) of the fractured maxillary right central incisor. **C)** The tooth was removed in two pieces with no flap using periostomes. **D)** The patient's tooth-and-veneer is shown luted to the screw-retained temporary abutment. **E)** The immediate provisional is ready to be inserted. **F)** The immediate postoperative appearance with PRP in place. **G)** The palatal view before closing the access opening. **H)** Postoperative radiograph. **I)** One year postoperative smile and with retraction (**J**) demonstrates ideal tissue health. **K)** The 1-year radiograph documents favorable bone height.

the surgery and the impression appointment for the final restoration.

Although early positive feedback from patients is always rewarding, it is the exceptional tissue health, along with maintenance of soft tissue contours and alveolar bone height, which provides the real impetus for pushing the envelope with this new approach to maximizing the esthetic potential of implants in the esthetic zone. The author considers it extremely important to avoid the use of cemented provisionals

when using the approach described in this article because the lack of flap access in these cases seems to rule out definitive, absolute avoidance of excess cement contaminating the peri-implant surgical environment. This commitment to avoidance of immediate cemented provisionals mandates that the straight-line access to the internal aspect of the implant be just palatal to the incisal edge of the tooth or provisional to avoid cutting through the incisal edge of the crown while modifying it for use as a provisional. Compromising the

incisal edge of a porcelain crown is unacceptable both structurally and esthetically, whereas compromising the incisal edge of a natural tooth (or denture tooth or composite crown) is undesirable from a perspective of the amount of chair time necessary to gain a good esthetic result while reestablishing incisal continuity. In either event, cutting through the incisal edge for screw access also commits the restorative dentist to additional chair time during the final impression appointment and any try-in appointments before insertion of the permanent crown.

Recently, Zeren³ described an approach to managing removal and replacement of teeth with implant-supported crowns in the esthetic zone. He also emphasized the importance and benefits of atraumatic extraction techniques. Instead of PRP, with the addition of autogenous bone only in site gaps between the socket and implant >1 mm, as described in this report, he used enamel matrix protein and freeze-dried bone allograft for all cases and seemed to achieve very good results. Another difference between Zeren's³ report and the present article is the fact that provisionals were not fixed to Zeren's implants immediately on placement.

Steigmann and Wang⁴ report on use of a submarginal "esthetic buccal flap" to allow access to graft labial-buccal fenestration defects in otherwise flapless immediate implant surgeries, with apparently excellent results. Their approach allows definitive management of osseous defects. In the present report, fenestration defects were managed by placing the autogenous bone and PRP through the socket-osteotomy. The healing results obtained through internal graft placement without flap access have been very good, as evidenced by the outcome with case 1. The one patient treated by the author who did have flap access had lost much of the labial plate because of trauma, with formation of a dehiscence defect rather than a fenestration.

At the very least, attaching "tall thin healing cuffs" (minimally functional fixed provisionals, as described herein) increases the length of the lever arm, imparting increased stress into the implant through lip and tongue pressure and through inadvertent pressure from the occasional food boluses, even if the opposing teeth do not quite touch the provisional. Is this presumptive increased risk of imparting perioperative instability counterbalanced by any benefit? In addition to offering the opportunity for ideal support of the soft tissues, it is the author's opinion that establishing positive contours permucosally improves the cleansability of the wound margin. Because plaque and debris accumulations can cause inflammation, thereby resulting in bone resorption, any improvement in postoperative cleanliness and tissue health has the potential to result in improved bone height on final healing. The

improved patient satisfaction of having a fixed provisional, thereby avoiding a flipper, the opportunity for ideal tissue support, and the possibility of improved tissue health do seem to offer sufficient benefit to warrant the presumptive increased risk.

The question then arises, how significant is this presumed increased risk? Del Fabbro et al.⁵ have published a review of survival rates for immediately loaded implants, including single implants. They cite 23 studies that included immediately loaded single maxillary implants, although only eight of these 23 studies included immediately loaded implants placed into extraction sites. The authors of this literature review⁵ computed a survival rate of 96.1% for the 336 immediately loaded implants placed into extraction sites compared to a 98.5% survival rate for immediately loaded implants placed into edentulous sites. The authors conclude that "(f)urther research is required to specifically address this comparison." It is difficult to disagree with their conclusion, although their review, along with the experiences of the author of this present report certainly seem to suggest that immediate loading of immediately placed implants must be considered a viable treatment option.

In the maxillary anterior segment, highly scalloped gingival margins tend to be the rule rather than the exception. As a consequence, placing the fixture platform at or just apical to the labial osseous crest has translated into the fixture being several millimeters subgingival and subcrestal interproximally. It is the author's opinion and experience that a machined conical abutment-implant interface allows for deep margins to be essentially free of inflammation, as noted in Figure 1K (the lining of the implant provisional socket is a darker red than the surface of the surrounding gingiva because of the presumption of it being lined with non-keratinized sulcular epithelium) and as evidenced by the lack of inflammation of the interdental papillae in all clinical photos.

Case 2 is one of a very few immediate provisionals that the author is aware of that loosened before the impression appointment for the permanent crown. As an aside, the esthetic outcome of the final restoration might have been improved in case 2 through modifying the height and shape of the gingival margin through esthetic crown lengthening before the final impression for the crown. Additionally, moving the contact point apically to within 5 mm of the crest of the bone, as described by Tarnow et al.⁶ and Grunder,⁷ would have allowed the gingival embrasure to be filled completely by the gingival papilla.

To date, all restorative dentists have chosen to use abutments and cemented crowns as the final restoration rather than screw-retained crowns. It is important to remind the restorative dentists that the abutments need to be prepared or fabricated with a margin that

follows the scalloping of the gingival margin to avoid proximal crown margins and cement lines that are deep subgingivally. It seems intuitive that the deeper the margin, the less likely it will be to clear all excess cement. Given the excellent marginal stability of these cases, having the cement line (margin) placed a single millimeter subgingivally has proved to be adequate for optimal esthetics while maximizing the chances for maintenance of ideal tissue health.

In Figure 2G, the articulating marks on the cingulum area of the adjacent left central incisor, and the extent of the relief on the lingual of the provisional that was necessary to avoid occlusal contacts. In centric occlusion, this patient had 7 mm vertical overlap in the incisor segment. It is the author's experience that cases with this sort of close vertical overlap can be extraordinarily challenging to gain an acceptable fit for a temporary removable partial while leaving sufficient acrylic to avoid fracture. The concerns about thin acrylic are exacerbated by placement of a healing cuff, whether immediately as a single-stage implant surgery or some weeks and months postoperatively when undertaken in a traditional two-stage approach to implant surgery. Because the composite retaining the tooth on the provisional abutment extends subgingivally, the technique described in this article offers the additional benefits of a precisely adjusted occlusal relationship and increased strength while offering support of the healing soft tissues and excellent esthetics.

CONCLUSIONS

This article describes, to the author's knowledge, a novel approach to immediate provisionalization of immediate implants, including modification of the patient's clinical crown for use as the screw-retained provisional, in the anterior segment. Using the existing crowns as the provisionals allows patients to leave on the day of surgery with essentially the same esthetic condition in which they arrived. Patients find it reassuring to know that they will be able to wear their own tooth (or a close match in cases where the patient's porcelain crown has fractured in the process of fabricating the provisional) as a fixed provisional crown. This seems particularly important in terms of

minimizing the sense of loss invariably experienced by patients as they go through the process of replacing a tooth in the esthetic zone.

ACKNOWLEDGMENTS

On three occasions the author has presented (receiving honoraria) portions of the material in this paper at continuing education courses sponsored by Astra Tech USA, Waltham, MA. The author does not own any Astra Tech stock and did not receive any financial support during the clinical treatment of cases described herein, including having paid full price for all implants and prosthetic components used. All patients paid full fees for the treatments rendered. This was a true "private practice" endeavor. Dr. Doug McMaster of Tucson, Arizona, took the photograph used in Figure 1K and placed the crown for case 1.

REFERENCES

1. Stanford CM, Wagner W, Baena RRY, et al. Multicenter clinical evaluation (FOCUS) of a fluoride modified dental implant (abstract 1488). IADR 85th General Session. Available at: http://iadr.confex.com/iadr/2007orleans/techprogram/abstract_88356.htm. Accessed June 25, 2006.
2. Asplund P, Ceder F. The FOCUS project. *Insight* 2006; 8:16-17.
3. Zeren KJ. Minimally invasive extraction and immediate implant placement: The preservation of esthetics. *Int J Periodontics Restorative Dent* 2006;26:171-181.
4. Steigmann M, Wang H-L. Esthetic buccal flap for correction of buccal fenestration defects during flapless immediate implant surgery. *J Periodontol* 2006; 77:517-522.
5. Del Fabbro M, Testori T, Francwtti L, Taschieri S, Weinstein R. Systematic review of survival rates for immediately loaded implants. *Int J Periodontics Restorative Dent* 2006;26:249-263.
6. Tarnow DP, Magner AW, Fletcher P. The effect of the distance from the contact point to the crest of bone on the presence or absence of the interproximal dental papilla. *J Periodontol* 1992;63:995-996.
7. Grunder U. Stability of the mucosa; topography around single-tooth implants and adjacent teeth: 1-year results. *Int J Periodontics Restorative Dent* 2000;20:11-17.

Correspondence: Dr. Brien V. Harvey, 899 N. Wilmot, E-2, Tucson, AZ 85711. E-mail: brien@drbrienharvey.com.

Accepted for publication October 12, 2006.